



Faculty

John Stone, MD, MPH
Director

David Hellmann, MD
Executive Director

Michael Regan, MD, MRCP
Assistant Professor of Medicine

Clinical Coordinators

Judy Harrison
Senior Clinic Coordinator

Chasity Harrison
Patient Care Coordinator

Research Staff

Misty Uhlfelder, MPH
Senior Research Coordinator

Amanda Moore
Research Coordinator

Delphine Paul
Research Coordinator

Lourdes Pinachos, RN
Clinical Trials Coordinator

From Kussmaul to Kawasaki Thumbnail sketches in the history of vasculitis

Vasculitis has plagued human beings for thousands of years. Writings from antiquity, including those of Hippocrates, describe patients with maladies that strongly resemble vasculitis. However, modern recognition of this group of diseases emerged less than 150 years ago. In this edition of the Newsletter, we begin a two-part series on the history of vasculitis.


The First Case:

Polyarteritis Nodosa (1866)

Hans Seufarth, a tailor's apprentice traveling from town to town in Germany to learn his trade, came to the medical clinic in Freiburg in 1866. He had felt unwell for perhaps several weeks, and noted numbness on two fingers of his right hand. Seufarth had the strength to walk to the second floor, where the clinic was located, but over the next few weeks the full panoply of his disease unfolded swiftly: fevers, a rapid heart rate, abdominal pain, widespread loss of nerve function, and the appearance of bumps under his skin.

possible diagnosis. His initial opinion was that a different type of worm infestation had caused Seufarth's disease.

The only remedies available in the 1860s (which smack of quackery today) were predicated upon misbegotten notions about the origins of disease. For poor Seufarth, the discovery of steroids and other effective (albeit toxic) vasculitis treatments were nearly a century away; Kussmaul and his colleagues could only provide supportive care. Not surprisingly, Seufarth died of his illness within several weeks of reaching the clinic at Freiburg. Eventually at autopsy



Dr. Adolf Kussmaul

Kussmaul recognized Seufarth's puzzling condition to be a new disease. He named the disease "periarteritis nodosa" (PAN) because of the nodular swellings observed in many of the patient's arteries. Decades later, the name of PAN was modified to polyarteritis nodosa.

Certain diseases of blood vessels were already known at the time of Kussmaul. Other doctors had unwittingly described patients with PAN in the literature, but none

(Continued on page 2)

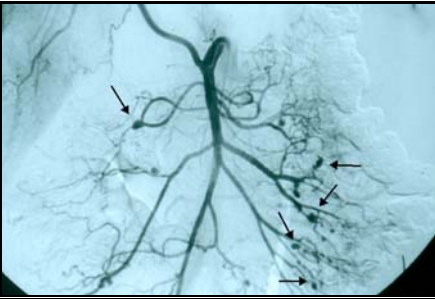Inside this Issue:

History of Vasculitis	1-3,7
FAQ	4
Patient Collage	5
A Happier Outcome	6-7
Welcome Lourdes	8

Kussmaul to Kawasaki: Continued

(Continued from page 1)

before Kussmaul had recognized its novelty. For two reasons, Kussmaul's recognition of PAN was a seminal event in the history of these diseases: 1) he realized that



Polyarteritis nodosa. Angiogram of the gastrointestinal tract. Arrows point to aneurysms of medium-sized arteries, typical of PAN.

the disease was associated with inflammation within the walls of blood vessels themselves; and, 2) he realized that Seufarth's symptoms and signs constituted a new disease. Kussmaul's report spelled the end of the Dark Ages for vasculitis.

For nearly 100 years after Kussmaul's report, most forms of vasculitis were thought to be variants of PAN. Between 1866 and 1966, doctors identified a new form of vasculitis approximately every decade. Newly-described diseases were usually classified based on their similarities to or differences from PAN. However, in the days before electronic medical journals, the Worldwide Web, and websites devoted to vasculitis (see page 5), educating physicians and patients about vasculitis was difficult. The first international consensus on the nomenclature of these diseases was not achieved until 1994.

In 1969, the first reports of an association of some cases of PAN with hepatitis B viral infections appeared. By the late 1990s, the advances in anti-viral medications permitted specific treatments directed against this virus, dramatically shortening the length of time patients were required to take prednisone and other dangerous immunosuppressive medications.

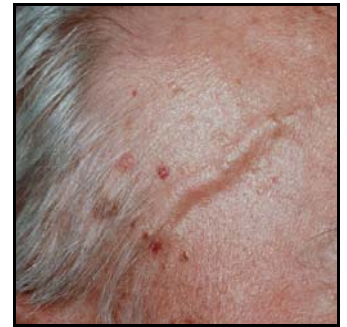As Jennifer Makowski's story indicates (see page 6), PAN continues to present enormous challenges in both diagnosis and treatment, but therapies for PAN have improved substantially since the time of Seufarth and Kussmaul.

Giant Cell (Temporal) Arteritis (1890)

Giant cell arteritis is the most common form of systemic vasculitis in the world. Its estimated prevalence in the

U.S. is 160,000 cases. Jonathan Hutchinson, an English surgeon, published the first case of giant cell arteritis in the British Archives of Surgery in 1890. His treatise was entitled: "...On a peculiar form of Thrombotic Arteritis of the aged which is sometimes productive of Gangrene". He described a gentleman's servant, Rumpole, a "tall, fine-looking man, rather thin and quite bald" who was "upwards of eighty and almost in his dotage". Rumpole complained of "red streaks on his head" caused by tenderness and swelling of his temporal arteries. The arteries were so tender that Rumpole was unable to wear his top hat.

Remarkably, following Hutchinson's initial description, giant cell arteritis did not surface again in the medical literature until forty-two years later, when Bayard Horton and colleagues at the Mayo Clinic performed the first temporal artery biopsy (1932). The first patients to undergo this procedure – now a routine outpatient procedure requiring only local anesthesia – were a 55 year-old farmwoman from Minnesota and a 68 year-old farmer from Nebraska.



Giant cell arteritis. Inflamed temporal arteries prevented Rumpole from wearing his top hat.

Polymyalgia Rheumatica (1957)

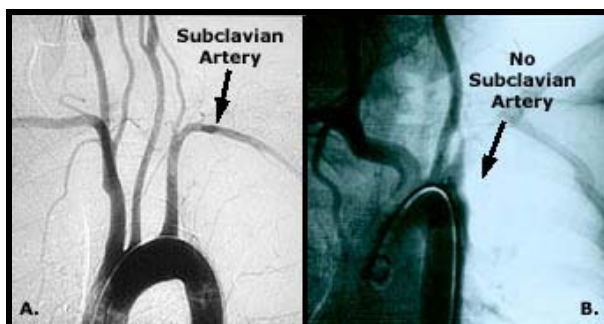
Up to 50% of all patients with giant cell arteritis have symptoms of polymyalgia rheumatica, a syndrome of intense aching and pain in the regions of the shoulders and hips. The pain is typically so disabling that patients are unable to comb their hair. Sometimes polymyalgia (meaning literally "many muscle aches") occurs on its own, without giant cell arteritis. Given that the prevalence of polymyalgia rheumatica in the U.S. is **450,000 cases**, the relatively late description of this condition by doctors is more than a little astonishing: the term "polymyalgia rheumatica" was coined by Stuart Barber, only 45 years ago. Before then, patients with this very common problem were usually misdiagnosed as having "rheumatism", or given or some other non-specific diagnosis.

(Continued on page 3)

(Continued from page 2)

Takayasu's Arteritis (1908)

Takayasu's arteritis, a disease of the aorta and its large branches that tends to afflict young women, is also known as "pulseless disease" because of its ability to obliterate the pulses in the wrist through severe narrowing of the arteries. At the 1908 Meeting of the Japanese Society of Ophthalmology, Makito Takayasu described a young woman with striking abnormalities of the arteries in the backs of her eyes (i.e., in her retinas). Using a hand-held ophthalmoscope, Takayasu saw "lumps" in the arteries surrounding the optic nerve. These lumps changed positions from day to day. Upon



Takayasu's arteritis. A. A normal aortic arch: smooth, widely patent vessels. B. Takayasu's arteritis. Arrow shows the complete absence of the right subclavian artery. The artery is blocked at its origin off the aorta.

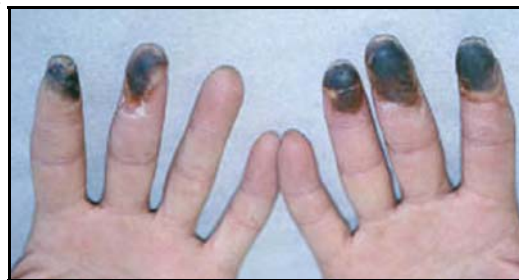hearing Takayasu's presentation, two other physicians in the audience recognized the eye findings as similar to those of several patients of their own. Their patients had the additional distinguishing feature of absent pulses in their extremities (despite being very much alive!). Over the ensuing years there was confusion about the best name for this disease. Thirty years after Takayasu's presentation, the suggestion of "Takayasu's arteritis" stuck, even though Takayasu himself did not realize the connection between the eye complications and large vessel vasculitis.

Buerger's Disease (1908)

Buerger's disease is associated with intense ischemia (lack of blood flow) to the hands and feet. In the same year as Takayasu's presentation, Leo Buerger, a pathologist at Mount Sinai Hospital in New York, evaluated a series of leg amputations from 11 men whose vascular disease was oddly premature (average age: 30).

Delving into their histories, Buerger noted that the first symptoms of this disease were "indefinite pains in the foot, in the calf of the leg, or in the toes, and particularly

of a sense of numbness or coldness whenever the weather is unfavorable". Despite writing eloquently about this



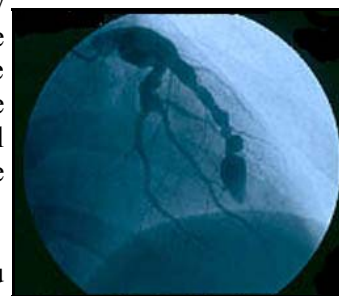
Buerger's Disease. Gangrene of several fingertips.

devastating disease, Buerger did not link the disease that he called "thromboangiitis obliterans" with its principal and only known risk factor, cigarette smoking.

We described a Vasculitis Center patient with Buerger's disease in the Summer Newsletter; (<http://vasculitis.med.jhu.edu>).

Kawasaki's Disease (1939)

In 1939, a 5 year-old girl presented to the Willard Parker Hospital in New York with a sore throat, high fever, and a red rash over her trunk. She appeared "desperately and acutely ill". The mucous membranes of her mouth were so inflamed that her tongue resembled a ripe strawberry. Several weeks later, while still in the hospital, the girl died suddenly of a ruptured aneurysm of a blood vessel in her heart. An autopsy showed multiple aneurysms of her coronary arteries, similar to those shown in the image. The nodular swellings of these vessels led the doctors to call this disease "infantile periarteritis nodosa".



Kawasaki's Disease. Aneurysms (outpouchings) of damaged heart blood vessels.

In 1961, Dr. Tomisaku Kawasaki evaluated a Japanese child with very similar disease features. This case spurred Kawasaki to perform a careful epidemiological study in Tokyo of what he suspected was a new disease. He identified 50 patients with a disorder he called "mucocutaneous lymph node syndrome", and carefully described its natural history and treatment. By the mid-1970s, people began to call

(Continued on page 7)

FREQUENTLY ASKED QUESTIONS:

Focus on “vasculitic neuropathy”, the damage to peripheral nerves that vasculitis may cause

“What are peripheral nerves?”

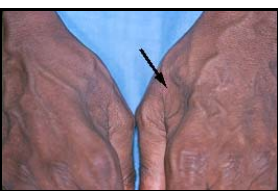Peripheral nerves are essential to a wide range of functions in humans. These nerves: 1) help us perceive pain, temperature, vibration, and all other sensations that are essential to interacting safely with our environment; 2) communicate messages from our brains and spinal cords to our muscles, telling them when and where to move; and, 3) maintain continuous stimulation of these same muscles, preserving normal muscle tone. Peripheral nerves course throughout the body and are particularly extensive on the skin. Recent research has shown that the functions of peripheral nerves and blood vessels are closely entwined. In fact, the positions of nerves in the body dictate the precise spots where blood vessel grow in the developing fetus.

One of the mysteries about vasculitis is why certain forms of this disease affect particular organs but not others. The forms of vasculitis that often affect peripheral nerves are: polyarteritis nodosa, microscopic polyangiitis, Wegener’s granulomatosis, the Churg-Strauss syndrome, and cryoglobulinemia.

“How did the vasculitis damage my nerves?”

Peripheral nerves require a steady supply nutrients, via blood. In vasculitis, damage to the blood vessels supplying these nerves leads to the loss of blood flow. The result is *infarction*, or death, of the involved nerve segments.

“What symptoms do damaged nerves cause?”



Muscle wasting (and weakness) in the “web space” between thumb and index finger.

The symptoms caused by vasculitic neuropathy depend on the type of nerve involved. Sensory nerve involvement leads to numbness and tingling. Motor nerve involvement leads to weakness and atrophy of the muscles whose function is directed by the specific nerves affected. The results of serious vasculitic neuropathy can be crippling and long-lasting.

“Will my nerves recover? Will they grow back?”

Fortunately, peripheral nerves do have a moderate capacity to regenerate, or grow back. Unfortunately, the process is a slow one. Nerves grow only 1/16 of an inch

every month. Therefore, recovery from extensive peripheral nerve damage takes months – sometimes years. Some patients never recover completely. The nerves must not only re-grow to sufficient length, they must also re-attach themselves to muscle in order to restore normal function. All of this takes time.

“How can I help my nerves grow back?”

The key to encouraging the recovery of peripheral nerve function is to control the underlying vasculitis. Maintaining adequate disease control through carefully monitored treatment gives nerves the best chance to recover. Physical and occupational therapy can also be essential in helping to maintain normal range of motion in affected extremities, so that the joints can still move when the nerves and muscles are again ready. And although patients are sometimes reluctant to use them, during the recovery process braces and orthotic devices help them continue to use their limbs in a manner that is as close to normal as possible.



Ankle-foot orthoses (braces) help patients with foot drop walk normally.

“If the nerves in my feet are dead, then why do I have pain in them? And what can I do about it?”

Peripheral nerves have only a very limited number of ways of responding to injuries, regardless of their cause. Pain is one such mechanism: damaged nerves often hurt, regardless of whether the cause is trauma, diabetes, excessive alcohol intake, or vasculitis.

Treating the pain of vasculitic neuropathy involves the use of “tricyclic” medications (the name refers to their chemical structure). These medications, which have well-defined safety profiles, are usually taken at bedtime. They often help with sleep, as well. Moreover, pain from nerve damage is frequently worst at night. The tricyclic medication that we prescribe most often is nortriptyline. When taking nortriptyline, it is important to begin at a very low dose (10 milligrams) and to increase the dose slowly, as tolerated. Gabapentin, which may also be helpful in relieving the pain caused by vasculitic neuropathy, can be used in combination with nortriptyline.

Vasculitis Center Collage

We enjoy seeing pictures of patients doing things they enjoy — away from the hospital and clinic!

New York Giants fan **Nicholas Polito**, in a photo from his career as a New Jersey State Trooper.



L.T. Richardson, his two granddaughters, Naomi and Sophia, and his favorite hunting dog, Queenie.



Jody Rosenzweig and the much-adored Mitzvah.




Katherine Magner, her husband David, and their daughter, Priscilla, enjoying the Eastern Shore summer.



Clare Goodman with her husband, Keith, on vacation in Amsterdam.

Arthur "Otts" Cayce, Jr. with his dog, Kodie, adopted from the German Shepard Rescue of Maryland.



Contribute to Research

The Johns Hopkins Vasculitis Center Website

See the fully updated website with larger pictures, Frequently Asked Questions, Archived Newsletters, and much more!
<http://vasculitis.med.jhu.edu>

Johns Hopkins is an active center for research. Much of our work in vasculitis is funded through grants. Other research support is made possible through private donations, large and small. If you would like to make a contribution to vasculitis research, please send your tax-deductible gift, payable to The Johns Hopkins Vasculitis Center. Our address is: 5501 Hopkins Bayview Circle, JHAAC Room 1B.1A, Baltimore, MD 21224. Questions about philanthropic giving may be directed to Anita Durel (410) 516-6606.

A Happier Outcome

By Dr. John Stone



Jennifer Makowski

Whenever I think about how Jennifer's case turned out – which is still often – I sigh with relief. In my mind, thoughts of that October day when I met her conjure the image of a wildcat ripping at her peripheral nerves; her disease, if unchecked, would have been no less lethal. I think of the lessons learned: another guise of this disease revealed; an alternative approach to treating it; and (once again) how the wishes of patients and their families are paramount. And I think, fortunately, how different her outcome was compared to that of Hans Seufarth, a German tailor about her age who lived — and — died 140 years ago (See “*From Kussmaul to Kawasaki*”, page 1).

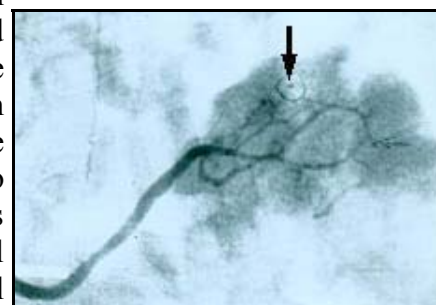
A wise doctor once told me that physicians learn the most when asked to see patients urgently. Such was the case that autumn, when I got a call from a colleague asking me to see a patient he thought had lupus. Jennifer Makowski, then 21 years old, had been ill for 6 months. Her illness had begun with calf pain that started after a hike. That next day, she developed a “migratory” arthritis: the joint pain and swelling jumped around from her ankles to her knees, to her elbows, and then to her wrists. A skin rash appeared over her legs and hands. She was found to have protein and blood in her urine. She underwent every test in the book, but as weeks turned into months, she remained without a diagnosis.

Yet her condition worsened, and the pace of her illness increased. She began to have severe, lightning-like pains in her extremities. Even the slightest touch triggered intense discomfort. She could not sleep. She was fired from her job because of “excessive” sick leave time. One day before I

saw her, her left index finger had turned purple, painful, and cold. On her way to clinic that morning, her father stopped the car so that she could vomit.

The telltale sign was her limp. She had a subtle “foot drop” on the right, a tendency of the foot to flop when walking because of muscle weakness in the lower leg. In compensation for this weakness, she lifted her knee high on the affected side when stepping, so as to avoid tripping and falling. In a patient with Jennifer's constellation of symptoms, foot drop is a red flag for vasculitis. To my way of thinking, the failure of all previous diagnostic tests to yield an answer made one form of vasculitis, polyarteritis nodosa (PAN), the leading contender. I admitted her to the hospital and treated her with steroids that night.

How to confirm the diagnosis? I was certain I knew what Jennifer had, but had to prove it. In treating vasculitis, there is no replacement for diagnostic certainty. At 6 a.m. the next morning, I spoke with Tony Venbrux, an interventional radiologist at Hopkins, told him my concerns, and said I would like him to perform an angiogram of the arteries to Jennifer's gastrointestinal tract. I still remember his immediate response: “We can do that”. His confidence buoyed my own spirits; I had already begun to worry about the long-term implications of treating Jennifer with our standard therapies.



Angiogram of Jennifer's splenic artery, showing a microaneurysm (arrow), diagnostic of PAN.

The angiogram was indeed diagnostic, revealing subtle microaneurysms in multiple arteries (see figure). These microaneurysms represented the same kind of nodules first observed by Kussmaul in

(Continued on page 7)

(Continued from page 6)

the case of Hans Seufarth. In the recovery room after her angiogram, I talked with Jennifer and her family about treatment. I had no doubt about the crippling, life-threatening nature of Jennifer's PAN. I strongly advocated the immediate use of our most powerful medication — cyclophosphamide — in the hope of arresting its progress. Jennifer and her family, dazed by the months of confusion surrounding her health and even more by the whirlwind of the previous 36 hours, had great fears of the potential complications of this medication: infertility, infection, the long-term risk of cancer, and others. After long discussions, they opted for steroid treatments alone.

Jennifer went home after 3 days. Over the next few weeks I sensed that the wildcat poised over her had slowly dropped its paw and left. I saw Jennifer nearly every week in clinic, however. She often called to request urgent appointments: she perceived every ache, pain, or mild discoloration of her index finger as a sign of recurrent vasculitis. Many days that winter I walked to clinic dreading: *"Today is the day we're going to have to start cyclophosphamide"*.

Five years later, I am confident that day will never come. Jennifer is cured. She has lost the weight

she gained on prednisone. Her steroid-induced acne is gone. Her index finger still sometimes hurts in the cold, a reminder of those bad days. But the muscle strength in her leg has returned to normal and there is no longer any hint of a foot drop. She took her last milligram of prednisone more than 4 years ago and returned to work — to a job she likes better. Jennifer now comes to clinic only once a year, more to pay a social call than anything else. Behind her smiling face is the knowing look of one who has faced a life-threatening illness at a young age, and survived. On one of these visits, Jennifer brought me a plastic barrel of Lifesavers. Although the candy is long gone, the plastic container, where my children save their nickels and dimes remains a treasured keepsake that tells the story of a happier outcome.



Dr. Stone with Jennifer Makowski at a recent visit.

Kussmaul to Kawasaki: Continued

(Continued from page 3)

mucocutaneous lymph node syndrome "Kawasaki's Disease". In 1987, a major therapeutic breakthrough in Kawasaki's came with the demonstration that the timely administration of gamma-globulin to acutely ill children is highly effective in preventing heart aneurysms, the major threat to patients' lives. The search for the cause of Kawasaki's disease continues.

In the interval of vasculitis history that spans the time from Kussmaul to Kawasaki (and beyond), our insight into the nature of these diseases has expanded enormously. In the past few years, we have moved into the molecular era of vasculitis research. We now recognize many critical subtleties between different

forms of vasculitis. Increasingly, these understandings allow us to tailor our treatments to the needs of individual patients. Our ultimate goal is to cure all of these diseases with interventions that leave patients free of unwanted side-effects. Substantial challenges remain, but we anticipate even greater progress in the months and years ahead.

In the Winter Edition: The histories of Wegener's granulomatosis, Churg-Strauss syndrome, Microscopic polyangiitis, Cogan's syndrome, Henoch-Schönlein purpura, Behcet's disease, and Cryoglobulinemia.

Introducing Lourdes



Lourdes Pinachos, RN

We are pleased to introduce our new Clinical Trials Coordinator, Lourdes Pinachos. Lourdes received her undergraduate degree in nursing from Catholic University in Washington, D.C. in 1998. She then worked in the District as both a medical and surgical nurse at Holy Cross and Suburban Hospitals. For the past year, she has practiced nursing in the research setting of the General Clinical Research Center at Johns Hopkins Bayview, an NIH-funded facility for clinical investigations. Lourdes commutes to Johns Hopkins Bayview from Washington, D.C. Her current projects are the Wegener's Granulomatosis Etanercept Trial (WGET) and the Wegener's Granulomatosis Genetics Resource (WGER).

We are pleased to report that WGET, the first randomized clinical trial ever conducted in Wegener's granulomatosis, has completed enrollment. WGET, coordinated at Johns Hopkins and involving 7 other major medical centers in the United States, enrolled the trial's final patient on September 30th. With 180 patients, WGET is the largest clinical trial ever in this disease. The trial will continue to follow patients on the experimental medication until October, 2003.

WE'RE ON THE WEB!
[HTTP://VASCULITIS.MED.JHU.EDU](http://VASCULITIS.MED.JHU.EDU)

Bayview Medical Center
5501 Hopkins Bayview Circle
JHAAC, Room 1B.1A
Baltimore, MD 21224
Scheduling Telephone: (410) 550-6825
Research Office Telephone: (410) 550-6816

**THE JOHNS HOPKINS
VASCULITIS CENTER**
